

Sex- and Age-related Changes of Trabecular Bone of Tibia in Growing Domestic Geese (*Anser domesticus*)

Anna CHARUTA, Małgorzata DZIERŻĘCKA, Edward CZERWIŃSKI, Ross Gordon COOPER and
Jarosław Olav HORBAŃCZUK

Accepted May 22, 2012

CHARUTA A., DZIERŻĘCKA M., CZERWIŃSKI E., COOPER R. G., HORBAŃCZUK J. O. 2012. Sex- and age-related changes of trabecular bone of tibia in growing domestic geese (*Anser domesticus*). Folia Biologica (Kraków) **60**: 205-212.

An analysis of radiological images of the spongy substance of the tibiotarsal bones in domestic goose (120 individuals) was performed for the first time. Based on radiographs obtained from radiological examinations conducted in the region of interest (80 x 90 mm²) of the proximal metaphysis, an analysis of the spongy substance of the tibia was performed with the Trabecula® programme in order to construct a map of trabeculae and identify their number, volume and density. The results were evaluated statistically using two-way ANOVA. Changes in the number, volume and density of radiological trabeculae of the tibiotarsal bone (TB) in geese from 4 to 16 weeks old were observed. The lowest number (6.34 per mm²), volume (1.50 % mm) and density (33.73 %) of radiological trabeculae in the proximal metaphysis of TB was reported in male geese at the age of 6 weeks. Similar tendencies were observed in females as well. It should be noted that the volume and density of radiological trabeculae of the tibiotarsal bone achieved a maximum value in males 12 weeks of age, whereas in females at 8 weeks of age. An inverse relationship between body weight and the number of trabeculae in domestic geese ($r = -0.28; P \leq 0.05$) was found. We also found a positive relationship between body weight and the volume of radiological trabeculae in domestic geese ($r = 0.43; P \leq 0.05$). During posthatching development, from the 4th week to slaughter maturity, a decrease in relative bone mass was observed. Negative changes in the trabecular structure combined with high weight gain could lead to bone deformities and locomotor problems in the studied geese.

Key words: Bone, geese, tibia, tibiotarsal, Trabecula®.

Anna CHARUTA, Vertebrates Morphology Department, University of Natural Sciences and Humanities in Siedlce, Konarskiego 2, 08-110 Siedlce, Poland.
E-mail: anna.charuta@neostrada.pl

Małgorzata DZIERŻĘCKA, Department of Morphological Sciences, Faculty of Veterinary Medicine, University of Life Sciences – SGGW, Nowoursynowska 166, 02-787 Warsaw, Poland.
Edward CZERWIŃSKI, Department of Bone and Joint Diseases, Jagiellonian University Medical College, Kopernika 32, in Kraków, 31-501 Kraków, Poland.

Ross Gordon COOPER, 5 Eurohouse, Dog Kennel Lane, Walsall WS1 2BU, England, UK.
Jarosław Olav HORBAŃCZUK, Institute of Genetics and Animal Breeding, Jastrzębiec, Postępu 1, 05-552 Magdalenka, Poland.

Contemporary breeding conditions of birds and their genetic selection in order to achieve a high body weight in the shortest period of time has created higher expectations concerning the mechanical resistance of the skeletal system of birds (FAGAN *et al.* 2009). A lack of balance in the growth of muscle mass and bones causes frequent deformities and fractures in birds all over the world (FLEMING 2004; HORBAŃCZUK *et al.* 2004; COOPER *et al.* 2008; TYKAŁOWSKI *et al.* 2010). Taking into account the scale of bone pathologies found in geese, it is worthwhile to examine the structure of the bone tissue during posthatching development in these birds.

There are many methods of intravital evaluation of the skeletal system in poultry, such as radiography – the most popular method for bone tissue examination in humans and animals, dual energy X-ray absorptiometry (HESTER *et al.* 2004), digital fluoroscopy (FLEMING *et al.* 2004), quantitative computed tomography (TATARA *et al.* 2004, 2005), as well as microtomography microCT (MARTINEZ-CUMMER 2006). Researchers have been increasingly interested in bone mineralization in poultry. Recent studies provide information on BMD and BMC (BAREIRRO *et al.* 2009; DZIERŻĘCKA & CHARUTA 2010; TALATY *et al.* 2009a, 2009b, 2010). Measurements of bone mineral density in a par-

ticular bone and posthatching development analysis can predict changes occurring in other parts of the skeleton. This is significant during the *in vivo* evaluation of the quality of the skeletal system.

Trabecula® is a programme allowing the determination of parameters of bone structure on a radiogram and predicts the resistance of bone tissue. It also allows tracking of the architectural system of trabeculae which plays an important role in shaping the resistance of bone tissue (CZERWIŃSKI 1994). The method is widely used in the diagnostics of fluorine and osteoporotic changes in humans (CZERWIŃSKI 1994), as well as in veterinary medicine to examine the structure of bones in farm animals (DZIERŻĘCKA 2006; DZIERŻĘCKA *et al.* 2007; CHARUTA *et al.* 2008). Trabecula® is a tool allowing the evaluation of bone tissue intravitaly, which helps to predict the probability of fractures and deformities of bird bones and helps in applying certain preventive treatments. This method, previously used only in humans, may be useful in diagnostics of young birds which are exposed to limb diseases as well as those which have a high body weight in relation to the developing skeleton.

The aim of the current investigation was to evaluate and determine the changes in the process of shaping the spongy substance in the post-hatching development of the tibiotarsal bone of oat geese bred with unlimited access to the yard and a well-balanced diet.

Material and Methods

The material consisted of radiograms of 120 tibiotarsal bones of White Kofuda Geese (W31). The geese were fed with a standard concentrate (produced by a commercial company Bacutil Bedlno, Poland) and contained 19.5 % protein, 11.72 MJ/kg at the beginning of fattening and 15.5 % protein and 12.14 MJ/kg at the end of fattening. The geese were kept for 16 weeks in a free-range system with unlimited access to the yard.

To evaluate the posthatching development of the spongy substance of the tibiotarsal bone in domestic geese, bones were taken from birds in 4-, 6-, 8-, 10-, 12- and 16-weeks of age. The study was conducted on 10 males and 10 females from each age group.

Slaughter and collection of material for research was conducted with the approval of the IIIrd Ethics Committee concerning experiments on animals (Resolution Nr 23/2009). Before slaughter, the animals were weighed and their sex was determined. Then, the tibiotarsal bones were isolated for further analysis. X-rays of the bones were generated with the use of an X-ray apparatus, EDR 750 B, applying radiation of 50 kv and intensity of

20 m As. The distance between the lamp and the cassette was 120 cm. Fresh bones were placed directly on the cassette without the use of a diffusion screen. Typical X-ray cassettes by Cawo (Primax Berlin GmbH, Germany) were used. The films were developed in an automatic darkroom (Kodak 35 MX, Frankfurt, Germany). The Trabecula® programme was used to analyse radiological images of the bones (CZERWIŃSKI 1994). Fragments in which the whole bone was visible were scanned. Scanning was performed at a resolution of 300 dpi.

The X-ray analysis was conducted in the so-called spongy bone area, where bone trabeculae could clearly be spotted with the naked eye. Images of the spongy substance with the highest diagnostic value were analysed.

A rectangular-shaped fragment (80 x 90 mm²) of all tibiotarsal bones was matched with the analysis of the structure of the spongy substance. It was extracted below the joint area near the proximal metaphysis. The analysed area did not include the cortical bone. (Fig. 1).

In order to establish which of the parameters are optimal while analysing the structure of the tibiotarsal bones, the number of trabeculae in given horizontal lines on the marked surface of the radiogram was determined by eye. Then the number was compared with the results achieved using the Trabecula® programme which depended on the selection of individual parameters.

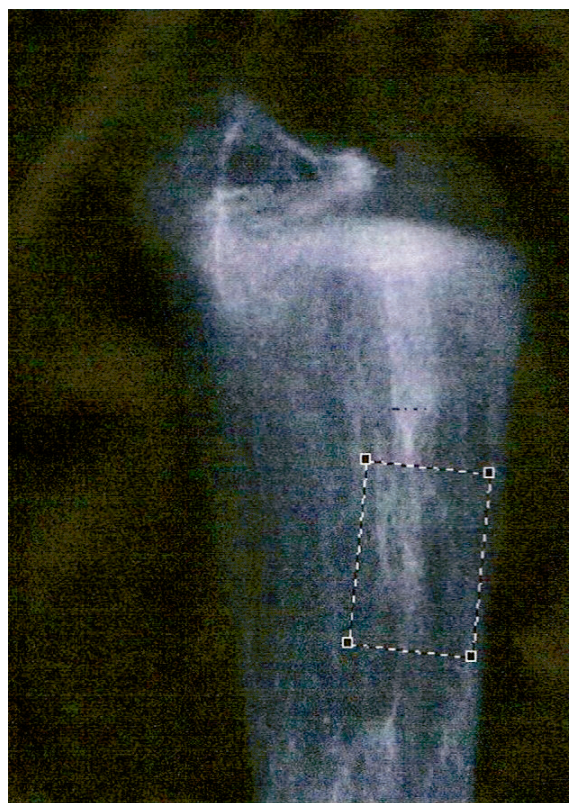


Fig. 1. A fragment of a radiogram of the tibiotarsal bone of a domestic goose with the marked area for analysis (80 x 90 mm²).

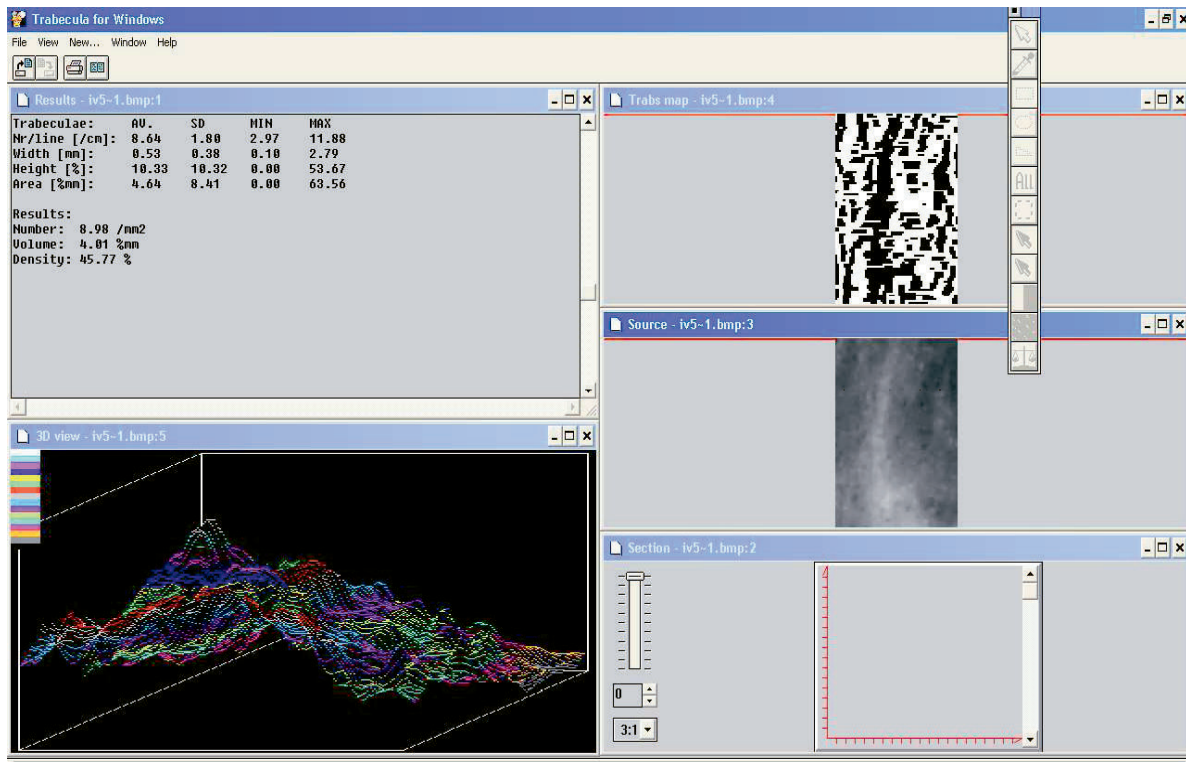


Fig. 2. Computer analysis of the radiological image using the Trabecula® programme.

The Trabecula® programme analysed radiological images recorded at a resolution of 0.096 mm and showed trabeculae according to a formulated definition. The programme was based on a compatible algorithm of recognising radiological trabeculae: in the form of defined parameters such as the angle and level of the microdensitometer curve. A comparison of the obtained map of trabeculae with the original radiogram revealed that the most credible image was achieved at the following parameters: angle – 20°, level – 40% and width – 200%. The programme recognises a segment of the microdensitometer curve on which it is possible to mark points of the described geometric figure. The figure exists in a quadrilateral shape with an ascending stage, a plateau and a descending stage with defined critical angles.

Having identified trabeculae on subsequent microdensitometer curves, the programme calculated the number of trabeculae, their volume and density. A 128 x 128 matrix recorded digitally was used in the analysis. Trabeculae were recognised as a segment of the curve whose rising and falling angles were 45°. According to this algorithm, the programme analysed 128 curves and made a map of the recognised trabeculae, then it calculated their characteristics for the whole surface as an average from the analysis of the 128 lines.

The programme was used to generate a trabeculae map and imal base measured given in % mm

and density given as a percentage of the surface covered with trabeculae for the whole area of the analysis.

Statistical analysis

The analyses included the following parameters: number, volume and density of radiological trabeculae, body weight as well as tibiotarsal bone weight. Moreover, the relative bone mass (bone weight divided by body weight x 100%) was calculated for males and females.

A two-way analysis of variance (variables included sex and age) was conducted in accordance with the model:

$$y_{ijl} = m + a_i + b_j + ab_{ij} + e_{ijl}.$$

where: y_{ij} – value of the studied feature, m – population average, a_i – effect of the level of A factor, b_j – effect of the level of B factor, ab_{ij} – effect of interaction between i and j , e_{ijl} – random error.

To define the differences in the studied quantitative features, which could be influenced by sex, the results were analysed separately for males and females.

Standard deviations (\pm SD) and arithmetical means (\bar{x}) were calculated. Differences between the mean values were determined with Tukey's test, at $P \leq 0.05$.

The relationship between body weight and the number of analysed radiological trabeculae as well as their volume, density and width were examined using coefficients of correlation and regression at $P \leq 0.05$.

Results

The obtained results are shown in Table 1:

The mean number of radiological trabeculae in the spongy bone of the proximal metaphysis in 4-wk-old geese both in males and females was similar – 9.6 mm², whereas in 6-wk-old male (6.34 mm²) and females (7.67 mm²) was the lowest. (Table 1).

The highest growth rate of body weight in geese during the posthatching period occurred between 4 and 6 weeks of age – 1400 g, whereas bone weight increased only by 10 g (Table 2). However, irrespective of the high increase in bone weight between the 4th and 6th week, the relative bone weight decreased from 1.0 % to 0.9 %. Thus, body weight grew much faster than bone mass. It is worth emphasising that from 8 weeks to 16 weeks, there was a decrease both in bone weight (from 34.58 g to 29.83 g, at $P \leq 0.05$) and in relative bone weight (from 0.8 % in 4 wk to 0.5 % in 6 wk, at $P \leq 0.05$) but the body weight constantly grew (Table 2). From among the 6 analysed developmental stages, 4-week geese of both sexes presented the highest relative bone weight, approx. 1%. In the 16th week,

Table 1

Average values (\bar{x}) and standard deviation \pm SD of the number, volume and density of radiological trabeculae of the tibiotarsal bones of oat geese as influenced by age (4, 6, 8, 10, 12 or 16 wk) sex and body weight

Item	Males(\pm SD)	Females(\pm SD)	Species average(\pm SD)
Number (mm²)			
4 wk	9.69 b, B \pm 1.00	9.46 a \pm 1.17	9.60 c, C \pm 1.02
6 wk	6.34 a, A** \pm 1.26	7.67 a** \pm 1.88	7.22 a, A \pm 1.76
8 wk	9.02 b, B \pm 0.90	9.96 a \pm 0.15	9.49 b, B, c, C \pm 0.12
10 wk	8.39b \pm 0.41	7.95 a \pm 1.20	8.17 a, A, b, B \pm 0.86
12 wk	9.60 b** \pm 0.57	7.89 a** \pm 0.73	8.08 a \pm 0.89
16 wk	8.45 b, B \pm 0.76	7.83 a \pm 0.69	7.96 a \pm 0.72
Volume (%mm)			
4 wk	1.63 a \pm 0.16	1.23 a, b \pm 0.41	1.48 a \pm 0.33
6 wk	1.50 a, A \pm 0.55	1.71 a, b \pm 0.48	1.64 a \pm 0.48
8 wk	2.38 a, b \pm 0.43	2.80 b \pm 0.38	2.60 c \pm 0.44
10 wk	2.33 a, b \pm 0.44	2.36 a, b \pm 0.47	2.35 b, c \pm 0.42
12 wk	3.03 b, B \pm 0.32	2.33 a, b \pm 0.38	2.41c \pm 0.42
16 wk	1.81 a \pm 0.14	1.78 a \pm 0.51	1.80 a, b \pm 0.45
Density (%)			
4 wk	44.16 b, B \pm 2.17	41.65 b \pm 3.19	43.19 a, b \pm 2.78
6 wk	33.73 a, A** \pm 2.82	37.97 a** \pm 2.26	36.55 a \pm 5.32
8 wk	43.56 b \pm 2.47	45.83 b \pm 0.27	44.69 b \pm 2.05
10 wk	41.45 b \pm 1.18	40.66 b \pm 4.33	41.05 a, b \pm 2.97
12 wk	46.37 b* \pm 0.94	41.33 b* \pm 1.52	41.89 a, b \pm 2.19
16 wk	40.44 b** \pm 1.7	36.51 a** \pm 11.45	37.35 a \pm 10.2
Body weight (g)			
4 wk	2362 a, A \pm 206	1960 a \pm 343	2207 a \pm 325
6 wk	3760 b, B \pm 531	3370 b \pm 270	3500 b \pm 400
8 wk	4233 c, C \pm 136	3790 c \pm 162	4011 c \pm 272
10 wk	4915 d, D \pm 427	4340 d \pm 193	4627 d \pm 434
12 wk	5450 d, e, D, E \pm 98	4693 d, e \pm 82.1	4777 d, e \pm 263
16 wk	5600 e \pm 200	4854 e \pm 182	5014 e \pm 364

a,b...e Means within a column with different superscripts are significantly different ($P \leq 0.05$).

A,B... ,E Means within a column with different superscripts are significantly different ($P \leq 0.01$).

*Means within a row are significantly different ($P \leq 0.05$).

**Means within a row are significantly different ($P \leq 0.01$).

Table 2

Mean values (\bar{x}) and standard deviation \pm SD of the bone length, bone weight, body weight and relative bone weight of tibiotarsal bones of domestic geese as influenced by age (4, 6, 8, 10, 12 or 16 week) and sex

Item	Males (\pm SD)	Females (\pm SD)	Pooled sexes (\pm SD)
Bone length (mm)			
4 wk	143.53 ^a \pm 0.04	143.77 ^a \pm 0.45	143.77 ^a \pm 0.31
6 wk	171.05 ^{b*} \pm 0.59	158.30 ^{b*} \pm 0.54	158.30 ^b \pm 0.82
8 wk	171.84 ^{b*} \pm 0.23	160.22 ^{b*} \pm 0.35	160.22 ^b \pm 0.67
10 wk	176.56 ^{c*} \pm 0.90	167.12 ^{c*} \pm 0.87	167.12 ^c \pm 0.97
12 wk	177.73 ^c \pm 0.65	171.35 ^c \pm 0.70	171.35 ^c \pm 0.72
16 wk	180.88 ^{c*} \pm 0.41	171.94 ^{c*} \pm 0.30	171.94 ^c \pm 0.57
Tibiotarsal bone weight (g)			
4 wk	24.46 ^a \pm 0.80	24.21 ^a \pm 2.13	24.34 ^a \pm 1.54
6 wk	34.06 ^{b*} \pm 1.16	32.08 ^{b*} \pm 1.92	33.07 ^b \pm 1.84
8 wk	34.58 ^b \pm 1.16	33.38 ^b \pm 0.87	33.93 ^b \pm 1.14
10 wk	31.70 ^b \pm 2.00	29.52 ^c \pm 0.57	30.97 ^c \pm 1.94
12 wk	30.10 ^c \pm 0.52	29.44 ^c \pm 0.32	29.70 ^c \pm 0.51
16 wk	29.83 ^{c*} \pm 0.47	29.36 ^{c*} \pm 0.86	29.57 ^c \pm 0.72
Body weight (g)			
4 wk	2362 ^a \pm 206	1960 ^a \pm 343	2207 ^a \pm 325
6 wk	3760 ^b \pm 531	3370 ^b \pm 270	3500 ^b \pm 400
8 wk	4233 ^c \pm 136	3790 ^c \pm 152	4011 ^c \pm 272
10 wk	4915 ^d \pm 427	4340 ^d \pm 193	4627 ^d \pm 434
12 wk	5450 ^{d,e} \pm 98	4693 ^{d,e} \pm 82.1	4777 ^{d,e} \pm 263
16 wk	5450 ^e \pm 200	4854 ^e \pm 182	5014 ^e \pm 364
Relative bone mass (%)			
4 wk	1.0 ^a \pm 0.0	1.2 ^a \pm 0.0	1.1 ^a \pm 0.0
6 wk	0.9 ^a \pm 0.00	1.0 ^a \pm 0.0	0.9 ^a \pm 0.0
8 wk	0.8 ^a \pm 0.0	0.9 ^a \pm 0.0	0.9 ^a \pm 0.0
10 wk	0.6 ^b \pm 0.0	0.7 ^b \pm 0.0	0.7 ^b \pm 0.0
12 wk	0.6 ^b \pm 0.0	0.6 ^b \pm 0.0	0.6 ^b \pm 0.0
16 wk	0.5 ^b \pm 0.0	0.6 ^b \pm 0.0	0.6 ^b \pm 0.0

^{a,b,...,e} Means within a column with different superscripts are significantly different ($P \leq 0.05$).

*Means within a row are significantly different ($P \leq 0.05$).

on the other hand, the relative bone weight was only 0.5% (Table 2).

It should be emphasised that deformities occurred most frequently (around 20 % in females and 40% in males) in 6-week-old geese. At this period of bone growth, a higher incidence of health problems connected with locomotory function was observed in geese. Moreover, a higher relation of the body weight to bones leads to extensive loading and bone deformities including fractures of the tibiotarsal bone (Fig. 3).

In 6-week-old domestic geese the number of radiological trabeculae significantly correlated with sex, whereas in males, the number depended on age, as well. The correlation between the number

of trabeculae and the body weight of domestic geese ($r = -0.28$; $P \leq 0.05$) proved that there was a relationship between these two features. The regression equation showed that when body weight increased by 1 g, the number of trabeculae dropped by 0.000364 mm^2 (Table 3).

The number of trabeculae increased in 8-week-old geese, both in males and females, and reached approximately 9.02 mm^2 and 9.96 mm^2 , respectively. It should be noted that the number of trabeculae decreased among geese of both sexes and between 12 and 16 weeks of age is lower than in 4 week old geese (Table 1).

Another studied parameter was the volume of radiological trabeculae of the tibiotarsal bone. The

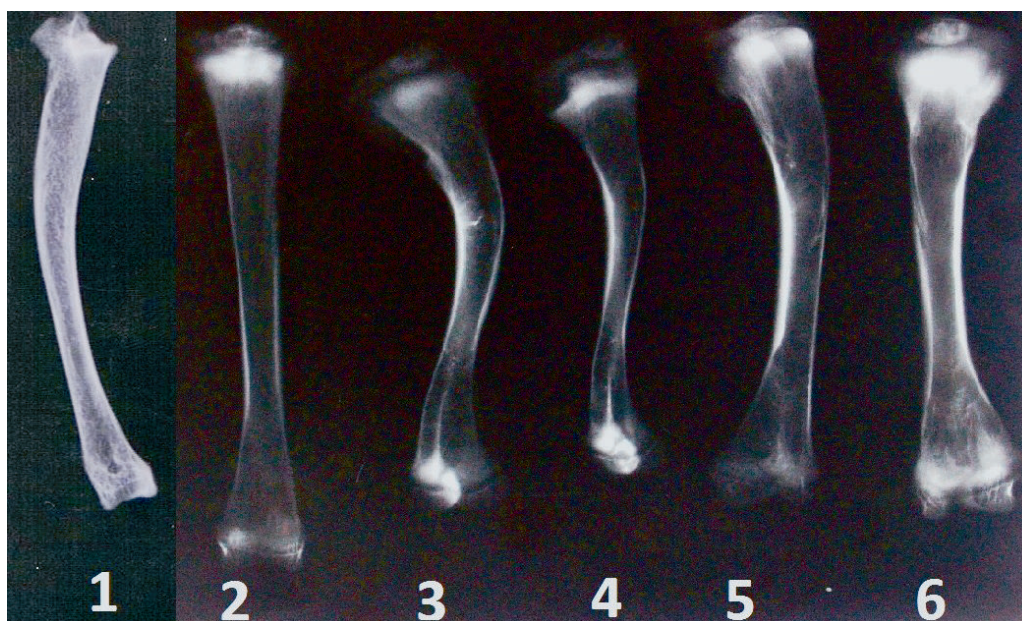


Fig. 3. Various forms of deformities of tibiotarsal bone in 6-week domestic geese. 1 – bowed bone of 6-week male; 2 – properly built tibiotarsal bone of 6-week male; 3, 4, 5 – deformations of the proximal metaphysis and the middle of the bone of 6-week males; 6 – deformed tibial bone of 6-week female domestic geese. Visible enlargements in epiphyses and metaphyses.

Table 3

Values of correlation coefficients between the studied features (body weight, number, volume and density of trabeculae) in domestic geese

Studied feature	domestic geese	
	Correlation coefficient	Regression equation
Body weight x number of trabeculae	-0.28*	$Y = 9.895 - 0.000364x$
Body weight x volume of trabeculae	0.43*	$Y = 1.004 + 0.000250x$
Body weight x density of trabeculae	-0.08	

*significant at $P \leq 0.05$

Explanation:

In domestic geese a negative relationship between the body weight and the number of trabeculae was observed. The regression equation shows that when the body weight increases by 1 g, the number of trabeculae falls by 0.000364 mm^2 .

There is also a relationship between the body weight and the volume of radiological trabeculae in domestic geese. If the body weight increases by 1 g, the volume rises by 0.000250 \% mm .

The relationships between the body weight of domestic geese and the density of radiological trabeculae were not recorded.

maximum value of this feature was achieved in males at 12 weeks of age, whereas in females at 8 weeks of age. In turn, the average density of trabeculae in the proximal metaphysis was the lowest in 6-week-old males and amounted to 33.73%. Significant differences between males and females ($P \leq 0.05$) were found in this parameter (Table 1).

The correlation between the volume of trabeculae and the body weight of domestic geese was $r = 0.43$; $P \leq 0.05$. When the body weight was bigger, the volume of trabeculae increased as well (Table 3).

The regression coefficient indicates that when the body weight increases by 1 g, the volume of trabeculae increases by 0.000250 \% mm (Table 3).

Discussion

Selecting the tibiotarsal bone as a model for research is justified as its proximal metaphysis contains large amounts of spongy substance in which metabolic processes are the most intense.

Therefore, pathological changes, e.g. symptoms of decreased bone density, are visible in the spongy substance quite early. Tibiotarsal bone in fast growing poultry is prone to disorders of the mineralisation process. The disorders in the spongy bone of the tibial metaphyses lead to bone deformities and fractures.

The deformities and fractures of TT bones and mineralisation disorders were recorded among meat type birds (turkeys, ducks, geese, chickens) (TYKAŁOWSKI *et al.* 2010). In slaughter turkeys, the deformities and disorders of mineralisation were caused by tibial dyschondroplasia and occurred in the cartilage of the proximal tibial epiphysis (POULOS *et al.* 1978; LYNCH *et al.* 1992; PETERS *et al.* 2002). Very often, tibial deformities in poultry were caused by decreased blood supply in bones (SIMSA *et al.* 2007), exceedingly fast growth (WILLIAMS *et al.* 2003) and vitamin deficiency – rickets (HUFF *et al.* 1999). Calcium and phosphorus deficiencies in the plasma were also the cause of rickets (BAR *et al.* 1987). Moreover, bones of birds kept in cages were more prone to fractures (JEDRAL *et al.* 2008). The deformities of long bones in poultry can result in a decline of production efficiency. Taking into consideration the range of pathologies, the following research was performed to examine the changes in the structure of spongy substance of the TT bone in domestic goose. With the help of the Trabecula® programme, it was recorded that in posthatching development, the lowest number and the lowest density of trabeculae were observed among 6-week-old geese, both males and females. At this age, the highest number of locomotor function disorders connected with deformation of tibia was reported (bow-shaped bones).

Similar results were obtained on ducks by CHARUTA *et al.* 2011, in which (for both sexes) the lowest number of radiological trabeculae per 1 mm² in the area of spongy bone of the proximal metaphysis was also reported at the age of 6 weeks and amounted to 10.34 mm².

On the basis of analysis of the bone tissue structure with the use of the Trabecula® programme, significant statistical differences between age groups of domestic geese were observed. At the age of 16 weeks, when the birds become sexually mature, the volume of trabeculae of the proximal metaphysis declines significantly in comparison with younger birds. Analysing the sex groups, no statistically significant differences concerning the volume of trabeculae between males and females were observed for a particular age. The volume of trabeculae depended only on age and was independent of sex. CHARUTA *et al.* (2011) reported that there were significant differences in the volume of radiological trabeculae depending on sex in 6-week-old ducks.

The average density of trabeculae as a percentage of a cube with the maximal and minimal base measured, given in % mm, in the proximal metaphysis was the lowest in 6-week-old males and amounted only to 33.73 %. The density of radiological trabeculae of the birds showed significant differences between males and females. In research conducted by CHARUTA *et al.* (2011), it was reported that among ducks the lowest density, expressed as a percentage of the surface covered with trabeculae for the whole area of the analysis, was characteristic for females and amounted to 44.62 %. On the basis of the conducted analysis, it was found that there are significant differences between sexes in the density of trabeculae in the proximal metaphysis of 6- and 16-week-old domestic geese. Density values depend on the age group and sex.

Similar results were observed in ducks in studies performed by CHARUTA *et al.* (2011). The density of trabeculae in 6-week-old ducks was the lowest as well. Macroscopic deformities of the tibiotarsal bones in 6-week-old males and females can be explained by the microscopic structure of the proximal metaphysis of the tibiotarsal bone. At that age, both the number of trabeculae and their density are the lowest in males and females. A relationship between body weight and density was not detected.

Research concerning changes in the density of poultry bones as influenced by age and sex was conducted by TALATY *et al.* (2009a, 2010). The authors analysed changes in mineralisation of the humeral and tibial bones in broiler chickens of both sexes from the second to the eighth week of life using dual energy X-ray absorptometry (DEXA). Mineral density was the largest in 4-week-old broiler chickens and slightly bigger in cocks (TALATY *et al.* 2009a). In domestic geese the highest density *in situ* was observed in the proximal metaphysis in 12-week-old males and 8-week-old females.

In conclusion the lowest number (6.34 mm²), volume (1.50 % mm) and density (33.73 %) of radiological trabeculae in the proximal metaphysis of the tibiotarsal bone was reported at the age of 6 weeks in males of the domestic goose. This may be associated with fractures and deformities of the tibiotarsal bones occurring mainly in 6-week-old males (40%).

The current research showed that the adaptation of the Trabecula® programme is useful for studying bone morphology at the microstructural level in birds, for example, the structure of the spongy substance of the tibiotarsal bone in the posthatching development of domestic geese. Applying this non-invasive method in orthopaedic diagnostics in birds is very useful because it allows the recognition of disorders in the spongy substance of birds.

References

- BAR A., ROSENBERG J., PERLMAN R., HURWITZ S. 1987. Field rickets in turkeys: relationship to vitamin D. *Poult. Sci.* **66**: 68-72.
- BARREIRO F. R., SAGULA A. L., JUNQUEIRA O. M., PEREIRA G. T., BARALDI-ARTONI S. M. 2009. Densitometric and biochemical values of broiler tibias at different ages. *Poult. Sci.* **88**: 2644-2648.
- CHARUTA A., MAJCHRZAK T., CZERWIŃSKI E., COOPER R. G. 2008. Spongy matrix of the tibiotarsal bone of ostriches (*Struthio camelus*) – a digital analysis. *Bull. Vet. Inst. Pulawy*, **52**: 175-178.
- CHARUTA A., DZIERŻEĆKA M., MAJCHRZAK T., CZERWIŃSKI E., COOPER R. G. 2011. Computer-generated radiological imagery of the structure of the spongy substance in the postnatal development of the tibiotarsal bones of the Peking domestic duck (*Anas platyrhynchos* var. *domestica*). *Poult. Sci.* **90**: 830-835.
- COOPER R. G., NARANOWICZ H., MALISZEWSKA E., TENNETT A., HORBAŃCZUK J. O. 2008. Sex-based comparison of limb segmentation in ostriches aged 14 months with and without tibiotarsal rotation. *J. South African Vet. Assoc.* **7**: 142-144.
- CZERWIŃSKI E. 1994. A quantitative measurement of changes appearing under the influence of fluoride in cortical and orbicular bone. Habilitation dissertation, Collegium Medicum UJ, Kraków, Poland. (In Polish).
- DZIERŻEĆKA M., CHARUTA A. 2006. Modern methods in the evaluation of bone tissue quality and possibility of their application in veterinary medicine. *Medycyna Wet.* **62**: 617-620. (In Polish).
- DZIERŻEĆKA M., CHARUTA A. 2010. The bone mineral density (BMD) and content (BMC) of the skeleton of the thoracic and the pelvic limb in the ostrich (*Struthio camelus* var. *domesticus*) as influenced by sex. *Bull. Vet. Inst. Pulawy*. **54**: 601-604.
- DZIERŻEĆKA M., MAJCHRZAK T., CZERWIŃSKI E., KOBRYŃ H. 2007. Digital assessment of radiograms of the spongy structure of the proximal phalanx of thoroughbreds and Arabian horses. *Medycyna Wet.* **63**: 1443-1447. (In Polish).
- FAGAN A. B., KENNAWAY D. J., OAKLEY A. P. 2009. Pinelectomy in the chicken: a good model of scoliosis. *Eur. Spine J.* **18**: 1154-1159.
- FLEMING R. H., KORVER D., MCCORMACK H. A., WHITEHEAD C. C. 2004. Assessing bone mineral density *in vivo*: digitized fluoroscopy and ultrasound. *Poult. Sci.* **83**: 207-214.
- HESTER P. Y., SCHREIWEIS M. A., ORBAN J. I., MAZZUCO H., KOPKA M. N., LEDUR M. C., MOODY D. E. 2004. Assessing bone mineral density *in vivo*: Dual Energy X-ray Absorptiometry. *Poult. Sci.* **83**: 215-221.
- HORBAŃCZUK J. O., HUCHZERMEYER F., PARADA R., PLAZA K. 2004. Four-legged ostrich (*Struthio camelus*) chick. *Vet. Rec.* **154**: 736.
- HUFF W. E., HUFF G. R., CLARK F. D., MOORE Jr. P. A., RATH N. C., BALOG J. M., BARNES D. M., ERF G. F., BEERS K. W. 1999. Research on the probable cause of an outbreak of field rickets in turkeys. *Poult. Sci.* **78**: 1699-1702.
- JENDRAL M. J., KORVER D. R., CHURCH J. S., FEDDES J. J. R. 2008. Bone mineral density and breaking strength of white leghorns housed in conventional, modified, and commercially available colony battery cages. *Poult. Sci.* **87**: 828-837.
- LYNCH M., THORP B., WHITEHEAD C. 1992. Avian tibia dyschondroplasia as a cause of bone deformity. *Avian Pathol.* **21**: 275-285.
- MARTINEZ-CUMMER M. A., HECK R., LEESON S. 2006. Use of axial X-ray microcomputer tomography to assess three-dimensional trabecular microarchitecture and bone mineral density in single comb white leghorn hens. *Poult. Sci.* **85**: 706-711.
- POULOS P. W. 1978. Tibial dyschondroplasia (osteochondrosis) in the turkey. A morphologic investigation. *Acta Radiol. Suppl.* **358**: 197-227.
- PETERS T. L., FULTON R. M., ROBERTSON K. D., ORTH M. W. 2002. Effect of antibiotics *in vitro* and *in vivo* avian cartilage degradation. *Avian Dis.* **47**: 75-86.
- SIMSA S., MONSONEGO ORNAN E. 2007. Endochondral ossification process of the turkeys (*Meleagris gallopavo*) during embryonic and juvenile development. *Poult. Sci.* **86**: 565-571.
- TALATY P. N., KATANBAF M. N., HESTER P. Y. 2010. Bone mineralization in cock commercial broilers and its relationship to gait score. *Poult. Sci.* **89**: 342-348.
- TALATY P. N., KATANBAF M. N., HESTER P. Y. 2009a. Life cycle changes in bone mineralization and bone size traits of commercial broilers. *Poult. Sci.* **88**: 1070-7.
- TALATY P. N., KATANBAF M. N., HESTER P. Y. 2009b. Variability in bone mineralization among purebred lines of meat-type chickens. *Poult. Sci.* **88**: 1963-1974.
- TATARA M. R., PIERZYŃOWSKI S. G., MAJCHER P., KRUPSKI W., BRODZKI A., STUDZIŃSKI T. 2004. Effect of alpha-ketoglutarate (AKG) on mineralization, morphology and mechanical endurance of femur and tibia in turkey. *Bull. Vet. Inst. Pulawy*. **48**: 305-309.
- TATARA M. R., SIERANT-ROŹMIEJ N., KRUPSKI W., MAJCHER P., ŚLIWA E., KOWALIK S., STUDZIŃSKI T. 2005. Quantitative computed tomography for the assessment of mineralization of the femur and tibia in turkeys. *Medycyna Wet.* **61**: 225-228. (In Polish).
- TYKAŁOWSKI B., STENZEL T., KONCICKI A. 2010. Selected problems related to ossification processes and their disorders in bird. *Medycyna Wet.* **66**: 464-469. (In Polish).